




ELSEVIER

Contents lists available at ScienceDirect

Journal of Equine Veterinary Science

journal homepage: www.j-evs.com

Original Research

Safety of Intra-Articular Gold Microimplants in Horses—A Randomized, Blinded, Controlled Experimental Study

Nina Märki^a, Stefan Witte^b, Stephan Kuchen^c, Stefan Reichenbach^{d,e}, Alessandra Ramseyer^b, Vincent Gerber^b, Claudia Spadavecchia^{a,*}^a Anaesthesiology Section, Department of Clinical Veterinary Medicine, Vetsuisse Faculty, University of Bern, Bern, Switzerland^b Swiss Institute of Equine Science, Department of Clinical Veterinary Medicine, Vetsuisse Faculty, University of Bern and Agroscope, Bern, Switzerland^c Laboratory of Experimental Rheumatology, Department of Rheumatology, Immunology, and Allergology, University Hospital and University of Bern, Bern, Switzerland^d Division of Clinical Epidemiology and Biostatistics, Institute of Social and Preventive Medicine, University of Bern, Bern, Switzerland^e Department of Rheumatology and Clinical Immunology/Allergology, Inselspital, Bern University Hospital, Switzerland

ARTICLE INFO

Article history:

Received 23 January 2017

Received in revised form 7 March 2017

Accepted 10 March 2017

Available online xxxx

Keywords:

Gold
Horse
Intra-articular
Microimplants
Berlock

ABSTRACT

Arthrogenic pain is a common problem in equids. Frequently used treatments such as systemic non-steroidal anti-inflammatory drugs or intra-articular steroids can lead to severe side effects if used repeatedly. Gold has been used since ancient times to treat a variety of conditions and has anti-inflammatory and immunomodulating properties. Results from clinical and in vitro studies suggest that local gold might provide a safe and effective alternative to alleviate articular pain. In particular, gold microimplants have been proposed to this end, but it is unknown if and how healthy joints react to this treatment. The aim of this study was to evaluate the safety of gold microimplants (Berlock-Micro-Implants) mixed with hyaluronic acid and injected into the middle carpal joint of nine healthy horses. Each horse was treated in one carpus and sham-treated on the contralateral. Lameness, carpal temperature increase, swelling, and reactions to joint palpation were observed in both treated and sham-treated carpi in the first week after needle arthroscopy and treatment. Significant differences between treated and sham-treated carpi were found only for mechanical nociceptive thresholds 4 days after treatment. Higher thresholds were found in treated joints compared with sham-treated joints. None of the outcome measures selected in the present study indicated systemic or local adverse effects specifically attributed to gold microimplants. In the absence of systemic and local adverse reactions to gold microimplants, the results of the present study support future clinical trials to test the pain-relieving efficacy of this treatment modality in subacute or chronic articular inflammatory processes in equine patients.

© 2017 Elsevier Inc. All rights reserved.

Ethics approval: This study was approved by the Cantonal Authority for Animal Experiments, Canton Bern and Vaud, Switzerland (BE105/12).

Authors contribution: SW, SR, VG, and CS conceived the study, participated in its design and coordination, and reviewed the manuscript. NM, SW, and AR were responsible for the clinical care of the horses and data collection. SK and NM carried out the laboratory analysis and both

interpreted the data obtained. NM and CS drafted the manuscript. All authors have read and approved the final manuscript.

* Corresponding author at: Claudia Spadavecchia, Department of Clinical Veterinary Medicine, Vetsuisse Faculty, University of Bern, Länggasse 124, 3012 Bern, Switzerland.

E-mail address: claudia.spadavecchia@vestsuisse.unibe.ch (C. Spadavecchia).

1. Introduction

Osteoarthritis (OA) is a common cause of pain and lameness in equids, it is a career limiting disease in both sport and leisure horses. The most frequently used treatments are oral or intravenous non-steroidal anti-inflammatory drugs (NSAIDs), or intra-articular steroids [1]. Despite their proven efficacy severe side effects might be encountered in case of prolonged therapy. This limits their applicability and safe alternatives are needed.

Gold has been used since ancient times for its anti-inflammatory and immunomodulating properties [2,3]. Originally conceived as a way to continuously stimulate acupuncture points [4], periarticular gold implants, several millimeters in diameter, have been used to obtain long-lasting pain control in OA [5–7]. Experimental studies showed that gold ions, the active component in aurotherapy, are released from implanted gold by dissolution, an extracellular process performed by macrophages. This can occur only when the implant is at least 20 μm in size as smaller particles are phagocytized and no gold ions are released [8,9]. Gold microimplants (20–40 μm) tested in vitro and in vivo in experimental animals have been patented for direct application in inflamed tissues, including joints (Berlock-Micro-Implants [BMI], Goldtreat ApS) [10]. For administration, BMI are mixed with hyaluronic acid (HA) to guarantee an adequate distribution. The local release of gold ions, with their anti-inflammatory activity, is enhanced in inflamed tissue, thus providing the rationale for intra-articular use of gold implants in equine OA. To date, no safety data for intra-articular BMI application can be found in the literature. Before initiating clinical trials focusing on the pain-relieving efficacy of BMI in equine OA, the occurrence of major adverse reactions needs to be ruled out. Only then it will be acceptable to recruit and treat client-owned horses with BMI.

The aim of this study was to evaluate the safety of intra-articular BMI mixed with HA in healthy horses. In each horse, one middle-carpal joint was treated with BMI mixed with HA while the other was treated with HA alone as a control. To detect any potential systemic or local adverse effects arising from the BMI treatment, several outcome measures were evaluated over a period of 3 months.

2. Materials and Methods

2.1. Study Design and Ethical Statement

The study, designed as a blinded, randomized, controlled, prospective experimental trial, was approved by the Cantonal Authority for Animal Experiments, Canton Bern and Vaud, Switzerland (BE105/12). All procedures were carried out under strict rescue analgesia regimen. If any horse showed signs of pain, reaching a score $>9/36$ on the composite pain scale (Appendix 1), or a lameness degree greater than 2/5 at any time during the study, further clinical evaluations were performed and analgesic treatment administered according to specific clinical signs. Flunixin (1 mg/kg IV) was administered in case of lameness ($>2/5$) and/or swelling (score ≥ 2) (Appendix 2). In case of persistent (>3 days) moderate or acute severe joint pain or swelling, joint flushing and intra-articular administration of morphine 0.1 mg/kg under general anesthesia was planned.

2.2. Animals

Nine healthy horses (eight females and one castrated male) belonging to the Swiss Institute of Equine Medicine without any signs of carpal pathology were included in the study. Horses had a median age of 10.2 years (range 10–18 years) and a median bodyweight of 580 kg (range 498–645 kg). Breeds included three Franche Montagnes horses, three Swiss Warmbloods, two Trotters, and one Hannoverian (Table 1). Eight horses were stabled together in an open barn with access to an outdoor pen, they were fed three times a day with hay and the resting area was bedded with straw, the access to water was unlimited. The remaining horse was stabled individually in a box bedded with shavings and was exercised daily on a walker or through paddock-turnout. This horse was fed haylage three times a day, with ad libitum access to water.

2.3. Inclusion Criteria

Before inclusion in the study, all horses underwent full clinical and hematological examinations. Radiological evaluation of the carpal joints was performed, with three radiographs taken of both carpi (dorsomedial-palmarolateral oblique, dorsolateral-palmaromedial oblique and

Table 1

Demographic data and random treatment assignment.

Horse	Breed	Age, y	Gender	Body Weight, kg	Treatment	
1	Hannoverian	19	Gelding	600	Sham-treated	Treated
2	Trotter	10	Mare	498	Sham-treated	Treated
3	Franche Montagnes	10	Mare	617	Treated	Sham-treated
4	Franche Montagnes	11	Mare	615	Treated	Sham-treated
5	Trotter	10	Mare	547	Treated	Sham-treated
6	Swiss Warmblood	13	Mare	615	Sham-treated	Treated
7	Swiss Warmblood	11	Mare	583	Treated	Sham-treated
8	Swiss Warmblood	14	Mare	618	Sham-treated	Treated
9	Swiss Mountain Horse	10	Mare	604	Treated	Sham-treated

Breed, age, gender, and body weight of the horses were included in the study and their treatment. Treated: Berlock Micro-Implants mixed with hyaluronic acid; Sham-treated: hyaluronic acid alone.

Table 2

Outcome parameters assessment schedule.

Study Phase	Study Day	Week	CPS	LLP	BS	SFS	US	RX	NA	T
Pretreatment	-14 to -7	-1/-2	x	x	x			x		
Treatment	0	0				x	x		x	x
Follow-up	1	1	x							
	2		x	x						
	3		x							
	4		x	x						
	5		x							
	6		x	x						
	7		x		x	x	x			
	14	2	x	x						
	30	4	x	x	x	x	x			
	60	8	x	x						
End of study	90	12	x	x	x	x	x	x	x	

Abbreviations: BS, blood sampling; CPS, composite pain score; LLP, lameness and local pain assessment, see [Appendix 2](#); NA, needle arthroscopy; RX, radiography; SFS, synovial Fluid sampling; T, intra-articular treatment (Berlock Micro-Implants mixed with hyaluronic acid) or sham-treatment (hyaluronic acid alone); US, ultrasound examination; x, assessed outcome parameter.

flexed lateromedial). Only horses that had normal blood-work, showed no radiological abnormalities, no lameness and no signs of pain were included in the study.

2.4. Outcome Measures

Outcome measures, as detailed below, were recorded by two investigators blinded to the treatment (NM and SW), before the treatment and up to 3 months thereafter according to the schedule shown in [Table 2](#).

2.4.1. Pain Score

A modification of the multifactorial numerical rating composite pain scale published by Bussieres et al [11] was used to evaluate pain and guide administration of rescue analgesia ([Appendix 1](#)).

2.4.2. Lameness and Symmetry Index

Subjective lameness examination was performed with the horses trotting in a straight line on a loose rope on a hard, even surface. A score from 0 to 5 (where 0: clinically sound and 5: non-weight bearing lameness, details in [Appendix 2](#)) was attributed to each horse before and after 1 minute of carpal flexion. Objective lameness evaluation was performed using the data collected from a poll-mounted three-dimensional accelerometer processed according to published algorithms [12,13] using MatLab (The MathWorks, Inc) by custom-made software (EquiGait) [14]. The generated symmetry index was interpreted using previously established values for non-lame horses [15]. Symmetry indexes of below 0.82 and greater than 1.18 indicated right and left forelimb lameness, respectively.

2.4.3. Carpal Variables

Joint swelling was scored using a 0–3 numerical rating scale ([Appendix 2](#)).

Carpal circumference was measured using a standard measuring band at the distal aspect of the accessory carpal bone.

Temperature of the carpus was quantified from frontal thermographic images of both carpi, collected with an infrared camera (InfraVet OptiRes D, VarioCAM, Infra Tech GmbH, Dresden, Germany) and analyzed with custom software (Exam Professional 5.8, InfraMedic GmbH, Germany). Horses were restrained in stocks for 30 minutes before the images were taken to avoid artifacts from ambient temperature changes and locomotion. The camera was positioned 1 m from the carpi for all readings. Temperature differences between the two carpi were calculated for each session. Differences of $\geq 1.25^\circ\text{C}$ between the carpi were considered clinically relevant [16].

Reactions to palpation of the middle carpal and carpo-metacarpal joints were scored using a 0–3 numerical rating scale ([Appendix 2](#)).

Mechanical nociceptive thresholds (MNTs) were determined using a calibrated hand-held algometer (FDN 200, Wagner Instruments, Greenwich CT) with a rubber tip 1 cm² in diameter and a maximal capacity of 20 kg. Pressure was applied perpendicular to the skin surface on seven predetermined anatomical landmarks along the front limb and was immediately released when the horse showed first signs of discomfort (e.g., lifting of the limb, twitching of the skin) or the pressure applied had reached 12 kg/cm² (cut-off value). A rate of pressure increase of approximately 2 kg/cm²/s was used for each measurement. Selection of landmarks was based on a previous report [17] and modified to assure evaluation of the area of interest ([Appendix 2](#)). Landmarks were evaluated in random order twice; a mean threshold value was calculated for each landmark and used for analysis.

Passive joint range of motion was measured as described by Liljebrink and Bergh [18] using a calibrated goniometer which could be fixed in place and read afterward using a standard set-square with integrated protractor.

Ultrasonographic evaluations of the synovial lining were performed by one of two examiners blinded to the treatment (SW, NM) using a portable ultrasound (M-Turbo; SonoSite, Bothell, WA) with a C11x/8–5 MHz linear transducer. Images of the joint-space between the radiocarpal bone and third carpal bone (dorsomedial) and the joint-space between the intermediate carpal bone and the third carpal bone (dorsolateral) were obtained in both B-Mode and Doppler-Mode. Each middle carpal joint was scored in accordance with the human sonographic definition of synovitis or synovial hypertrophy as per OMERACT 7 [19] on a 0–3 numerical rating scale. Scores were defined as 0: normal synovial lining; 1: mild hypoechoic synovial thickening; 2: moderate hypoechoic synovial thickening; 3: marked hypoechoic synovial thickening.

2.4.4. Needle Arthroscopy

Needle arthroscopy was performed to allow thorough evaluation of the intra-articular architecture of both middle-carpal joints immediately before treatment administration and 3 months thereafter. Horses were premedicated with 0.03 mg/kg acepromazine IM (Prequilan, Arovet AG, Switzerland) and sedated with a bolus of 0.05 mg/kg methadone (L-Polamivet, MSD Animal

Health GmbH, Switzerland) and 0.05 mg/kg romifidine (Sedivet, Boehringer Ingelheim, Germany) IV. Sedation was maintained by IV continuous rate infusion of 0.05 mg/kg/h methadone and 0.05 mg/kg/h romifidine in Ringer Lactate (Laboratorium Dr. G. Bichsel AG, Switzerland) titrated to effect. After routine preparation for surgery, lidocaine (Lidocaine 2% Streuli, G. Streuli & Co. AG, Switzerland) was injected subcutaneously (2 mL) and intra-articularly (20 mL) to distend the joint during endoscopy. Subsequently, a semirigid, 1.2 mm (outer diameter), 10° optic needle endoscope with a working length of 100 mm (BioVision, Golden, CO) was used to evaluate the middle carpal joint and standard images were obtained. In case of abnormal findings, a thorough description of the visualized altered structures was provided. All examinations were carried out by the same experienced orthopedic surgeon (SW). Time to perform the procedure was recorded. Flunixin meglumine (1 mg/kg IV) (Flunixin, Dr. E. Graeb AG, Switzerland) was administered postoperatively. The horses were confined to a box stall for 2 days before returning to their normal stabling and routine.

2.4.5. Blood and Synovial Fluid Analysis

Venous blood was collected for routine hematology, biochemical evaluation, and to determine serum amyloid A (SAA) concentration.

Synovial fluid samples were collected into plain tubes. An aliquot was diluted 1:20 in isotonic NaCl 0.9% and the number of nucleated cells immediately determined by a blinded investigator using a Neubauer counting chamber on a Leica microscope with 40× magnification. The remaining synovial fluid was centrifuged at 1,200 g to pellet cells and cell-free supernatant frozen in 1 mL aliquots and stored at –80°C until further analysis.

Levels of IL-1 β , TNF- α , Aggrecan Chondroitin Sulfate and Substance P in the synovial fluid were determined according to the manufacturers protocol using the following commercially available ELISA kits: GSI Equine IL-1 β ELISA Kit- Synovial Fluid (Genorise Scientific, Inc), GSI Equine TNF alpha ELISA Kit- Synovial Fluid (Genorise Scientific, Inc), Aggrecan Chondroitin Sulfate 846 Epitope (CS846 ELISA, IBEX Pharmaceuticals Inc, Canada), Substance P EIA Kit (Cayman Chemical Company, Ann Arbor, MI).

2.5. Treatment

Each horse underwent bilateral carpal treatment on day 0; immediately after needle arthroscopy and synovial fluid sampling, one joint (randomly determined) was injected with one vial of BMI mixed with 2 mL HA (treated) while the other was injected with 2 mL HA alone (sham-treated) (Table 1).

One vial of BMI consisted of 10 mg of gold (approximately 36,000 particles, 20–40 μ m in size). Before administration, HA (20 mg, Ostenil, TRB Chemedica S.A., Switzerland) was aseptically injected into the vial and shaken until the gold particles were adequately suspended. All horses were treated within two consecutive weeks.

2.6. Statistics

Analysis was performed with the statistical computing package R. Descriptive statistics were calculated for all outcome measures and medians and ranges reported. The data were analyzed at individual time points using a linear regression model and over time using a linear regression model with horse-specific random effects on the treatment difference. All models were stratified by horse to acknowledge that each horse was both treated and sham-treated and a two-sided alpha level of 0.05 for statistical testing was used.

3. Results

Main results are summarized in Table 3.

3.1. Pain Score

No signs of pain were observed for any horse at any time point during the study. The highest score recorded on the composite pain scale was 3/36.

3.2. Lameness and Symmetry Index

Subjective and objective lameness examinations showed mild to moderate degrees of forelimb lameness in five of nine horses in the first week after treatment. Horses 3, 5, 6, and 7 showed lameness on the sham-treated limb while horse 4 was lame on the treated limb. However, only two of the horses (horses 4 and 5) were needed to be treated with a short course of NSAID for lameness and swelling of the carpal and metacarpal region on days 4, 5, and 6. After 3 days, the treatment was discontinued as both swelling and lameness had resolved. On day 30, all horses were sound. On day 60, two horses (horses 2 and 5) showed mild lameness, both on the sham-treated limb. A thorough orthopedic examination and diagnostic perineural blocks localized pain to the hoof in both horses. On day 90, all nine horses were sound. Since the conclusion of the experimental phase 3 years ago, horses included in the study have been closely observed for 1–3 years. None of the horses were lame due to a clinical relevant carpal pathology.

3.3. Carpal Variables

Local swelling of the carpi was noticed in all horses at least during the first week after arthroscopy. Five horses showed a similar degree of swelling in both carpi; two horses (horses 4 and 5) showed more swelling in the treated carpi while in further two horses (horses 3 and 8), the sham-treated carpi were more swollen.

Compared with baseline, on average, all horses had an increase in carpal circumference in the first week after treatment in both carpi. Although overall this appeared more pronounced in the sham-treated joints, there was no statistically significant difference compared with the treated joints and all carpi were within 0.5 cm difference in circumference 90 days after treatment.

Five of the nine horses showed no significant temperature difference between the treated and sham-treated carpi at all times. In horse 1, the treated carpus had a

Table 3

Main results.

Outcome Parameter	Baseline	Week 1	Day 14	Day 30	Day 60	Day 90
MNT 2 treated, kg/cm ²	10.9 (7, 12)	9.5 (4.9, 11.3)	10.3 (6, 12)	10.6 (7.8, 12)	10.6 (6.2, 12)	11.7 (6.7, 12)
MNT 2 sham, kg/cm ²	10.5 (6.9, 12)	9.1 (5.2, 11.5)	10.3 (7.2, 12)	10.6 (8.9, 12)	11 (8.9, 12)	11.1 (6.9, 12)
MNT 3 treated, kg/cm ²	12 (5.9, 12)	9.4 (4.7, 10.4)	12 (5.9, 12)	11.3 (7.9, 12)	11.8 (7.8, 12)	10.3 (6.3, 12)
MNT 3 sham, kg/cm ²	12 (8.5, 12)	8.5 (4.9, 12)	10.2 (6.2, 12)	10.9 (8.6, 12)	12 (9.4, 12)	10.6 (7.7, 12)
MNT 5 treated, kg/cm ²	11 (7, 12)	9.5 (5.6, 12)	9.2 (6, 12)	10.3 (5.8, 12)	10.6 (7.6, 12)	10.7 (5.7, 12)
MNT 5 sham, kg/cm ²	10.5 (5.3, 12)	8.7 (5, 11.6)	9.7 (6.7, 12)	10.4 (8, 12)	11.1 (9.1, 12)	10 (6.8, 12)
Carpal flexion treated, °	26 (16, 35)	23 (17, 40)	22 (14, 39)	22 (15, 43)	21 (16, 37)	20 (17–23)
Carpal flexion sham, °	26 (16, 34)	21 (15, 30)	22 (13, 33)	22 (14, 30)	21 (17, 27)	20 (14, 25)
Circumference treated, cm	31 (29, 34)	32 (30, 35)	32 (30, 34)	31 (29, 34)	32 (29, 34)	31 (30, 34)
Circumference sham, cm	31 (30, 33)	32 (30, 34)	32 (30, 34)	31 (29, 33)	31 (30, 34)	32 (30, 34)
Symmetry Index, score	1.01 (0.9, 1.22)	1 (0.7, 1.75)	1.09 (0.65, 1.65)	0.87 (0.75, 1.27)	1.1 (0.52–1.37)	1 (0.87, 1.18)
Aggrecan treated, ng/mL	9,716 (5,476, 20,629)	8,220 (5,226, 21,569)		6,229 (3,416, 13,156)		8,439 (3,149, 30,277)
Aggrecan sham, ng/mL	6,276 (5,340, 24,079)	8,734 (4,816, 50,844)		10,775 (5,798, 37,405)		8,400 (3,252, 15,263)
IL-1 beta treated, ng/mL	0.126 (0.09, 0.168)	0.128 (0.079, 0.192)		0.105 (0.066, 0.161)		0.109 (0.066, 0.154)
IL-1 beta sham, ng/mL	0.128 (0.061, 0.186)	0.105 (0.09, 0.211)		0.132 (0.107, 0.196)		0.087 (0.063, 0.198)
TNF-alpha treated, ng/mL	0 (0, 0.091)	0 (0, 0.298)		0 (0, 0.271)		0 (0, 0.23)
TNF-alpha sham, ng/mL	0 (0, 0.069)	0 (0, 0.301)		0 (0, 0.338)		0 (0, 0.02)
Substance P treated, pg/mL	7 (6, 9)	8 (5, 18)		8 (5, 14)		7 (4, 16)
Substance P sham, pg/mL	8 (5, 13)	8 (5, 18)		7 (6, 12)		6 (5, 18)

Abbreviations: MNT, mechanical nociceptive threshold; TNF, tumor necrosis factor.

Median values and ranges for the main outcome parameters at baseline, week 1, days 14, 30, 60, and 90 after treatment (Berlock Micro-Implants mixed with hyaluronic acid)/sham treatment (hyaluronic acid alone). Mechanical nociceptive thresholds are reported for landmarks 2, 3, and 5. No significant differences ($P < .05$) were found at any of the reported time point between treated and sham-treated joints.

relative increase of 3.5°C on day 30. Horse 3 had a higher reading in the sham-treated carpus on days 4 (10.25°C) and 6 (4.6°C), as did horse 8 on day 6 (2.8°C) and horse 6 on day 90 (1.8°C).

In two horses (horses 1 and 2), palpation of the carpi was not painful at any time. Horses 8 and 9 were scored 1 at a single time point, whereas horses 5 and 6 were scored 1 repeatedly on both carpi. Horses 3 and 7 were scored 1 or 2 on palpation of the sham-treated carpus and horse 4 at palpation of the treated carpus at several time points during the first 14 days.

There were no significant differences in MNTs between treated and sham-treated limbs except for landmark 3 on day 4; treated joints had statistically significant higher MNTs than sham-treated joints ($P = .009$; Fig. 1).

Six of nine horses showed no significant changes in range of motion during the 90-day period. Two horses showed a temporary, reduced range of motion compared with baseline, one in the treated limb (horse 4) and one in the sham-treated limb (horse 3), which had returned to baseline by day 90.

Three of nine horses showed no ultrasonographic joint changes. Horse 7 had a score of 1 in the left middle carpal joint before treatment only. Horses 2, 8, and 9 showed a score of 1 on both treated and sham-treated carpi at different time points and horses 4, 5, and 6 had a score of 1 on the sham-treated carpus at different time points. No horse had ultrasonographic changes on day 90.

3.4. Needle Arthroscopy

In four joints of the 18 joints examined on day 0, clear images could not be captured due to hemorrhage. On day 0, a small full thickness lesion was noted on the weight-bearing surface of the fourth carpal bone in horse 8 and of the second carpal bone in horse 9. Both defects were unchanged at the second arthroscopy (day 90). Time to perform the procedure ranged between 30 and 90 minutes (average 63.3 minutes) on day 0, and between 30 and 55 minutes (average 38.9 minutes) on day 90. At 90 days, gold particles could be seen in the region of the lateral palmar intercarpal ligament of the left middle carpal joint in horse 9.

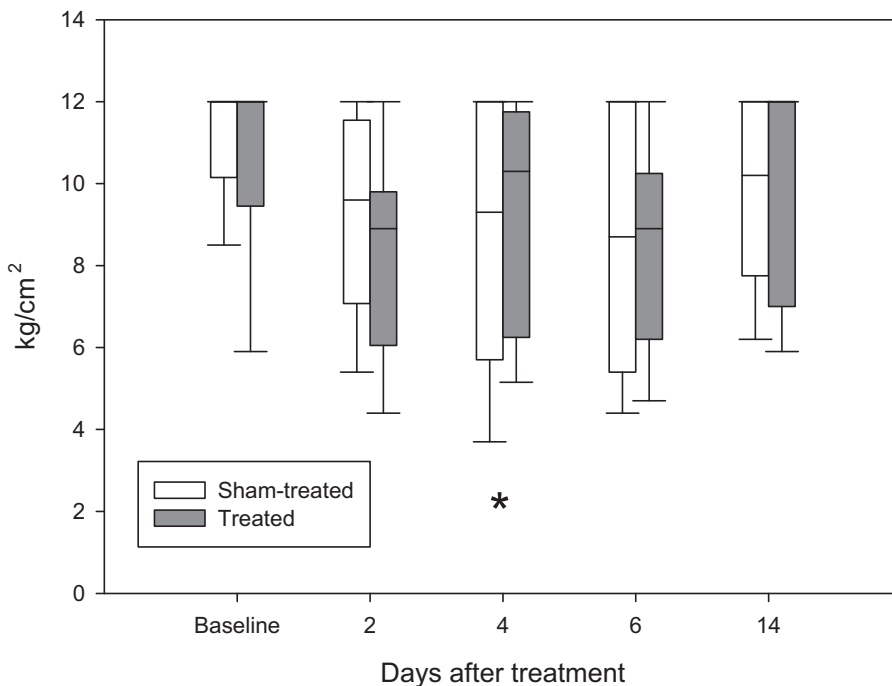


Fig. 1. Box and whiskers plots representing the medians (midline), 75% and 25% percentiles (upper and lower quartiles, respectively) and ranges (upper and lower whiskers) of mechanical nociceptive thresholds (MNTs) measured on the dorsal aspect of the midbody of the intermediate carpal bone (landmark 3) of treated joints (dark grey) and sham-treated joints (white). *Significant difference between treated and sham-treated joints were detected 4 days after treatment administration.

3.5. Blood and Synovial Fluid Analysis

Compared with baseline, hematology, serum chemistry, and SAA values showed no significant difference throughout the study. No values were outside the normal range at any time point.

Cell count in all synovial fluid samples was below 100 cells/ μ L at all time points, therefore differentiation was not performed as inflammatory effusion was not suspected. For CS846 and substance P, all values were within the normal range, whereas for IL-1 β and TNF- α all values were below or within the normal range. No differences between treated and sham-treated joints were found.

4. Discussion

The current study aimed to evaluate the safety of intra-articular gold microimplants mixed with HA in horses. Nine healthy experimental horses without any signs of pathology in the carpal region had their middle carpal joint unilaterally treated with BMI mixed with HA while the contralateral side was sham-treated with HA alone.

Our findings indicate that no major clinically relevant differences between the treated and the sham-treated joints were detected during the whole study period for any of the outcome measures evaluated.

To recognize as many potential adverse effects of intra-articular BMI on joint homeostasis, a large number of outcome parameters were included. Several diagnostic imaging techniques lend themselves for this purpose

in vivo. We chose ultrasonography for the serial evaluation of the synovial membrane, as this method is easy to perform, noninvasive, and provided a real time detection of pathological intra-articular changes [20]. Furthermore, needle arthroscopy was chosen for real-time macroscopic assessment of the target structures as it has been proposed as a minimally invasive technique allowing direct visualization without the need for general anesthesia. A thin needle endoscope was used to visualize the middle carpal joints in standing horses, as previously described [21,22]. The findings of the present study question just how minimally invasive this procedure is, as a relatively high incidence of lameness, swelling, and increased local sensitivity to palpation and pressure were observed during the first week following surgery. Despite the fact that optimal intraoperative sedation and analgesia was provided and that the smallest endoscope available was used, adequate patient cooperation was vital for surgery to take place without complications. Complications (intra-articular hemorrhage, articular and periarticular trauma) resulting in the signs observed in the first week after surgery, were more frequent in those horses that were least cooperative during the procedure. For future application, a mechanical fixation system might help to keep the correct limb positioning over time, with the carpus slightly lifted and flexed. Furthermore, well instructed personnel should be available to optimize the procedure while reducing risks of trauma.

The administration of HA in combination with BMI represents a further risk factor for side effects of treatment. Occasional adverse reactions to synthetic HA ("joint flare"),

lasting 3–5 days, have been described 1–3 days after administration in horses and humans [23,24]. As the viscosity of HA was needed to provide adequate distribution of the gold microimplants [10] in the treated joints, HA (and not saline) was also used as the control in the sham-treated joints. Hyaluronic acid as a confounding safety factor could therefore be largely excluded.

Significant differences between treated and sham-treated limbs were found only for MNTs as measured by algometry. Higher thresholds were found in the treated carpi than in the sham-treated carpi on day 4, on landmark 3, corresponding to the dorsal aspect at the midbody of intermediate carpal bone. Testing of mechanical nociceptive threshold is a method commonly used to assess local sensitivity to mechanical stimulation in humans [25]. Using a calibrated spring-loaded instrument, it is possible to quantify the pressure necessary to evoke pain when applied to a predefined anatomical landmark. Higher thresholds correspond to lower pain responses. In an experimental model of carpal OA, mechanical nociceptive threshold testing of the carpal region has been previously validated in horses and shown to be useful in differentiating between affected and nonaffected limbs as well as to quantify postoperative nociceptive sensitization [17]. In the present study, lower baseline threshold values in the carpal area were found compared with the previously published reference values; this discrepancy can likely be explained by the decreased rate of pressure increase applied (approximately one-fifth of the previously adopted rate in the present study). This rate was chosen as the operator (NM) was able to provide more reliable results. Similar rates have been previously described in human studies [25,26].

In addition to the higher MNTs found in the treated carpi, other local variables, such as temperature, swelling, reaction to palpation, and carpal circumference showed a similar clinical trend, with lesser adverse reactions being detected in the treated limbs. This may be interpreted as early postoperative analgesic and/or anti-inflammatory effect of gold in the treated joints. Further clinical studies are necessary to confirm this clinical impression.

Besides the clinical outcome measures, a panel of synovial molecular biomarkers, each reflecting specific intra-articular processes, was selected to assess articular health in the present study. The proinflammatory cytokines TNF- α and IL-1 β together with substance P, a neuropeptide known to accompany articular pain and inflammation, would be expected to increase in the face of BMI-induced articular inflammation [20,27]. In case of direct or indirect damage from BMI to cartilage matrix homeostasis, the epitope 846 of chondroitin should also increase, reflecting enhanced aggrecan turn-over [28,29]. No increases were noted in this study. Arthrocentesis was first performed 7 days after treatment to avoid further mechanical insults to the operated joint and possible partial removal of gold particles. The results of routine joint fluid analyses at four time points throughout the study showed no clinically or statistically significant differences between the treated and the sham-treated carpi and no deviations from baseline values. The absence of increase in cell counts and of catabolic, pain and inflammatory biomarkers observed in this

study indicates that BMI did not adversely affect synovial fluid homeostasis in healthy equine joints.

Although gold particles were seen arthroscopically in one horse at 90 days, the distribution of potentially toxic particles was not further evaluated. Previous studies [30] investigating the permeability of synovium in healthy and diseased human knees showed that synovial microvessels are permeable to a molecule radius of up to 1.75–40 nm. Although gold particles 1–2 nm in size have been shown to be cytotoxic [31], no toxic effects on vital organs could be demonstrated after intra-articular injection of 13 and 50 nm gold particles in an arthritis model in rats [32]. In the latter study, joint swelling and histological changes of the joint decreased significantly when treated with repeated nanogold injections. As nanogold particles are promptly phagocytized by macrophages, repeated administration is necessary to obtain a persistent anti-inflammatory effect [8]. In contrast, one single injection of microgold particles (as in the case of BMI) is expected to allow permanent release of gold ions, thus establishing longer-lasting local therapeutic levels [8,10,33].

The gold particles used in the present study had a diameter of 20–40 μm and were injected into healthy joints. Migration outside of the joint and a systemic effect are therefore unlikely. Furthermore, the low concentration of gold ions potentially leaving the joint [8] is not expected to cause systemic toxic effects. No changes in SAA concentrations, a reliable and very sensitive marker of systemic inflammation and infection [34,35] were seen over the study period. As the first blood sample for SAA determination was collected 7 days after treatment, we might have missed acute changes of this parameter.

General signs of pain were monitored by the use of a multidimensional pain score, previously validated in an equine model of experimentally induced arthritis [11] and slightly modified for the purposes of the present study. The highest score attributed to any horse at any time point was 3/36, indicating minimal or no systemic pain signs throughout the study attributable to systemic adverse reactions of BMI. These findings support the absence of both systemic and extensive local inflammatory effects after BMI injection.

The present study was limited to a follow-up period of 90 days. This duration was considered sufficient for adverse reactions to BMI treatment to become manifest. Furthermore, all horses included in the study have been under continuous supervision since the end of the study. They have been regularly reevaluated for a minimum of 1 year up to 3 years and none of the horses ever showed lameness due to a carpal pathology. Ex-vivo histological articular tissues examination would have provided stronger evidence of safety, but would have needed a terminal study design. A further limitation of the present study is the low number of subjects included. Indeed, to conclusively demonstrate absence of adverse effects in studies on medications or implants for human use, considerably higher subject numbers are required.

While a higher number of horses would have been helpful to draw more reliable conclusions, the robust study design and the fact that each horse acted as its own control make it unlikely that a higher number of horses would have altered the results.

5. Conclusion

Over the primary study period of 90 days, we were unable to determine systemic or local detrimental effects of a single administration of gold microimplants injected with HA into the middle carpal joint of healthy horses. Given the absence of acute adverse findings during the primary study period as well as during the long-term clinical follow-up of 1–3 years, the results of the present study indicate that the treatment is safe and thus support the performance of clinical trials testing efficacy in established subacute or chronic inflammatory processes.

Acknowledgments

We are grateful to Corsin Heim and Judith Howard for technical assistance, Valda and Richard Nixon for their help with the statistics and Michael Bartlett for linguistic support.

The Berlock-Micro-Implants (BMI) and the hyaluronic acid used in this study were sponsored by GOLDTREAT ApS, Denmark. None of the authors have any financial or personal relationships that could inappropriately influence or bias the content of the paper.

References

- [1] Goodrich LR, Nixon AJ. Medical treatment of osteoarthritis in the horse – a review. *Vet J* 2006;171:51–69.
- [2] Danscher G, Larsen A. Effects of dissolucytotic gold ions on recovering brain lesions. *Histochem Cell Biol* 2010;133:367–73.
- [3] Travnicek Z, Starha P, Vanco J, Silha T, Hosek J, Suchy Jr P, et al. Anti-inflammatory active gold(I) complexes involving 6-substituted-purine derivatives. *J Med Chem* 2012;55:4568–79.
- [4] Durkes TE. Gold bead implants. *Probl Vet Med* 1992;4:207–11.
- [5] Hielm-Bjorkman A, Raekallio M, Kuusela E, Saarto E, Markkola A, Tulamo RM. Double-blind evaluation of implants of gold wire at acupuncture points in the dog as a treatment for osteoarthritis induced by hip dysplasia. *Vet Rec* 2001;149:452–6.
- [6] Jaeger GT, Larsen S, Soli N, Moe L. Double-blind, placebo-controlled trial of the pain-relieving effects of the implantation of gold beads into dogs with hip dysplasia. *Vet Rec* 2006;158:722–6.
- [7] Jaeger GT, Larsen S, Soli N, Moe L. Two years follow-up study of the pain-relieving effect of gold bead implantation in dogs with hip-joint arthritis. *Acta Vet Scand* 2007;49:9.
- [8] Danscher G. In vivo liberation of gold ions from gold implants. Autometallographic tracing of gold in cells adjacent to metallic gold. *Histochem Cell Biol* 2002;117:447–52.
- [9] Larsen A, Stoltenberg M, Danscher G. In vitro liberation of charged gold atoms: autometallographic tracing of gold ions released by macrophages grown on metallic gold surfaces. *Histochem Cell Biol* 2007;128:1–6.
- [10] Danscher G. In: Patent US, editor. Medicament and method of treatment of patients with heavy metals; 2010. United States. Patent Number: US 7,655,261 B2.
- [11] Bussieres G, Jacques C, Lainay O, Beauchamp G, Leblond A, Cadore JL, et al. Development of a composite orthopaedic pain scale in horses. *Res Vet Sci* 2008;85:294–306.
- [12] Pfau T, Witte TH, Wilson AM. A method for deriving displacement data during cyclical movement using an inertial sensor. *J Exp Biol* 2005;208:2503–14.
- [13] Warner SM, Koch TO, Pfau T. Inertial sensors for assessment of back movement in horses during locomotion over ground. *Equine Vet J Suppl* 2010;417–24.
- [14] Starke SD, Willems E, May SA, Pfau T. Vertical head and trunk movement adaptations of sound horses trotting in a circle on a hard surface. *Vet J* 2012;193:73–80.
- [15] Buchner HFF, Savelberg HHCM, Schamhardt HC, Barneveld A. Head and trunk movement adaptations in horses with experimentally induced fore- or hindlimb lameness. *Equine Vet J* 1996;28:71–6.
- [16] Soroko M, Henkiewski R, Filipowski H, Jodkowska E. The effectiveness of thermographic analysis in equine orthopedics. *J Equine Vet Sci* 2013;33:760–2.
- [17] Haussler KK, Hill AE, Frisbie DD, McIlwraith CW. Determination and use of mechanical nociceptive thresholds of the thoracic limb to assess pain associated with induced osteoarthritis of the middle carpal joint in horses. *Am J Vet Res* 2007;68:1167–76.
- [18] Liljebriink Y, Bergh A. Goniometry: is it a reliable tool to monitor passive joint range of motion in horses? *Equine Vet J Suppl* 2010;676–82.
- [19] Wakefield RJ, Balint PV, Szkudlarek M, Filippucci E, Backhaus M, D'Agostino M-A, et al. Musculoskeletal ultrasound including definitions for ultrasonographic pathology. *J Rheumatol* 2005;32:2485–7.
- [20] de Grauw JC. Molecular monitoring of equine joint homeostasis. *Vet Q* 2011;31:77–86.
- [21] Frisbie DD, Barrett MF, McIlwraith CW, Ullmer J. Diagnostic stifle joint arthroscopy using a needle arthroscope in standing horses. *Vet Surg* 2014;43:12–8.
- [22] Mahlmann K, Koch C, Bodo G. Diagnostic endoscopy of the navicular bursa using a needle endoscope by direct or transthecal approach: a comparative cadaver study. *Vet Surg* 2015;44:816–24.
- [23] Martens PB. Bilateral symmetric inflammatory reaction to hylan G-F 20 injection. *Arthritis Rheum* 2001;44:978–9.
- [24] Goldberg VM, Coutts RD. Pseudoseptic reactions to hylan viscosupplementation: diagnosis and treatment. *Clin Orthop Relat Res* 2004;130–7.
- [25] Arendt-Nielsen L, Nie H, Laursen MB, Laursen BS, Madeleine P, Simonsen OH, et al. Sensitization in patients with painful knee osteoarthritis. *Pain* 2010;149:573–81.
- [26] Binderup AT, Arendt-Nielsen L, Madeleine P. Pressure pain threshold mapping of the trapezius muscle reveals heterogeneity in the distribution of muscular hyperalgesia after eccentric exercise. *Eur J Pain* 2010;14:705–12.
- [27] Sutton S, Clutterbuck A, Harris P, Gent T, Freeman S, Foster N, et al. The contribution of the synovium, synovial derived inflammatory cytokines and neuropeptides to the pathogenesis of osteoarthritis. *Vet J* 2009;179:10–24.
- [28] Frisbie DD, Ray CS, Ionescu M, Poole AR, Chapman PL, McIlwraith CW. Measurement of synovial fluid and serum concentrations of the 846 epitope of chondroitin sulfate and of carboxy propeptides of type II procollagen for diagnosis of osteochondral fragmentation in horses. *Am J Vet Res* 1999;60:306–9.
- [29] de Grauw JC, van de Lest CH, van Weeren PR. Inflammatory mediators and cartilage biomarkers in synovial fluid after a single inflammatory insult: a longitudinal experimental study. *Arthritis Res Ther* 2009;11:R35.
- [30] Simkin PA, Bassett JE. Pathways of microvascular permeability in the synovium of normal and diseased human knees. *J Rheumatol* 2011;38:2635–42.
- [31] Pan Y, Neuss S, Leifert A, Fischler M, Wen F, Simon U, et al. Size-dependent cytotoxicity of gold nanoparticles. *Small* 2007;3:1941–9.
- [32] Leonaviciene L, Kirdaite G, Bradunaite R, Vaitkiene D, Vasiliauskas A, Zabulyte D, et al. Effect of gold nanoparticles in the treatment of established collagen arthritis in rats. *Medicina (Kaunas)* 2012;48:91–101.
- [33] Larsen A, Kolind K, Pedersen DS, Doering P, Pedersen MO, Danscher G, et al. Gold ions bio-released from metallic gold particles reduce inflammation and apoptosis and increase the regenerative responses in focal brain injury. *Histochem Cell Biol* 2008;130:681–92.
- [34] Jacobsen S, Thomsen MH, Nanni S. Concentrations of serum amyloid A in serum and synovial fluid from healthy horses and horses with joint disease. *Am J Vet Res* 2006;67:1738–42.
- [35] Hultèn C, Grönlund U, Hirvonen J, Tulamo RM, Suominen MM, Marhaug G, et al. Dynamics in serum of the inflammatory markers serum amyloid A (SAA), haptoglobin, fibrinogen and α 2-globulins during induced noninfectious arthritis in the horse. *Equine Vet J* 2002;34:699–704.

Appendix 1

Composite pain scale.

Criteria	Score
Physiologic data	
Heart rate	
Normal compared with initial value	0
11%–30% increase	1
31%–50% increase	2
>50% increase	3
Respiratory rate	
Normal compared with initial value	0
11%–30% increase	1
31%–50% increase	2
>50% increase	3
Digestive sounds	
Normal	0
Decreased motility	1
No motility	2
Hypermotility	3
Rectal temperature	
Normal	0
Variation less 1°C	1
Variation less 1.5°C	2
Variation less 2°C	3
Behavior	
Interactive behavior	
Pays attention to people	0
Exaggerated response to aud. stim.	1
Excessive to aggressive resp. to aud. stim.	2
Stupor, prostration, no resp. to aud. stim.	3
Appearance	
Bright, lowered head/ears, no reluctance to move	0
Bright, alert, occasional head movements, no reluctance to move	1
Restlessness, pricked ears, abnormal facial expr. pupils dilated	2
Excited, continuous body movement, abnormal facial expr.	3
Sweating	
No obvious signs of sweating	0
Damp to the touch	1
Wet to the touch, beads of sweat over entire body	2
Excessive sweating, beads of water running off horse	3
Kicking at abdomen	
Quietly standing, no kicking	0
Occasional kicking at abdomen (1–2 times per 5 minutes)	1
Frequent kicking at abdomen (3–4 times per 5 minutes)	2
Excessive kicking at abdomen (>5 times per 5 minutes)	3
Pawing on the floor	
Quietly standing, no pawing	0
Occasional pawing (1–2 times per 5 minutes)	1
Frequent pawing (3–4 times per 5 minutes)	2
Excessive pawing (>5 times per 5 minutes)	3
Posture	
Stands quietly, normal walk	0
Occasional weight shift, slight muscle tremors	1
Non-weight bearing, abnormal weight distribution	2
Analgesic posture (attempts to urinate), prostration	3
Head movement	
No evidence of discomfort, head straight	0
Occasional head movement, laterally or vertically (1–2 times in 5 minutes)	1
Lip curling (1–2 times per 5 minutes), occasional look at flank	1
Intermittent and rapid head movements (3–4 times per 5 minutes)	2
Lip curling (3–4 times per 5 minutes), frequent look at flank	2
Continuous head movement, excessively looking at the flank	3
Lip curling (5 times per 5 minutes)	3
Appetite	
Eats hay readily	0
Hesitates to eat hay	1
Shows little interest in hay, eats very little	2
Neither shows interest in nor eats hay	3
Total score	/36

Adapted from Bussièrès et al [11].

Appendix 2. Local outcome measures and lameness

Day of Study: _____ **Date:** _____

Horse name _____ Gender _____ Age _____

Breed _____ Weight _____

Joint palpation

Reaction to palpation

	0 = Absent	1 = Mild	2 = Moderate	3 = Severe
Left	<input type="checkbox"/>	<input type="checkbox"/>	<input type="checkbox"/>	<input type="checkbox"/>
Right	<input type="checkbox"/>	<input type="checkbox"/>	<input type="checkbox"/>	<input type="checkbox"/>

Degree of joint swelling

	0 = Absent	1 = Mild	2 = Moderate	3 = Severe
Left	<input type="checkbox"/>	<input type="checkbox"/>	<input type="checkbox"/>	<input type="checkbox"/>
Right	<input type="checkbox"/>	<input type="checkbox"/>	<input type="checkbox"/>	<input type="checkbox"/>

Carpal circumference (at distal aspect of accessory carpal bone)

Right front: Left front:

Mechanical nociceptive thresholds determination

Points	Left		Right	
	1	2	1	2
1. Dorsal 1/3 MCII medial to digital extensor tendon				
2. Dorsal aspect of third carpal bone over extensor carpi radialis tendon				
3. Dorsal aspect of midbody of intermediate carpal bone				
4. Dorsal aspect of midbody of the radial carpal bone medial to extensor carpi radialis tendon				
5. Craniolateral aspect of the midbelly of the extensor carpi radialis muscle at the height of the elbow				

(Haussler et al [17])

Thermography.

Findings right front;

Findings left front;

Subjective lameness evaluation.

Evaluation in-hand, at a trot, on the straight line (*AAEP Lameness score*)

0 = clinically sound; 1 = inconsistently lame under certain circumstances; 2 = consistently lame under certain circumstances; 3 = consistently lame at the trot on the straight line; 4 = lame at the walk; 5 = non-weight bearing if lameness which leg:

0	1	2	3	4	5
<input type="checkbox"/>	<input type="checkbox"/>	<input type="checkbox"/>	<input type="checkbox"/>	<input type="checkbox"/>	<input type="checkbox"/>

Flexion test (negative or positive)

Right front: Left front:

Goniometer measurement (angle at maximum passive flexion without resentment)

Right front: Left front:

Objective lameness evaluation:

- as determined using a poll-mounted inertial sensor:
Symmetry index:
If lameness is detected which leg: